

QUIZ

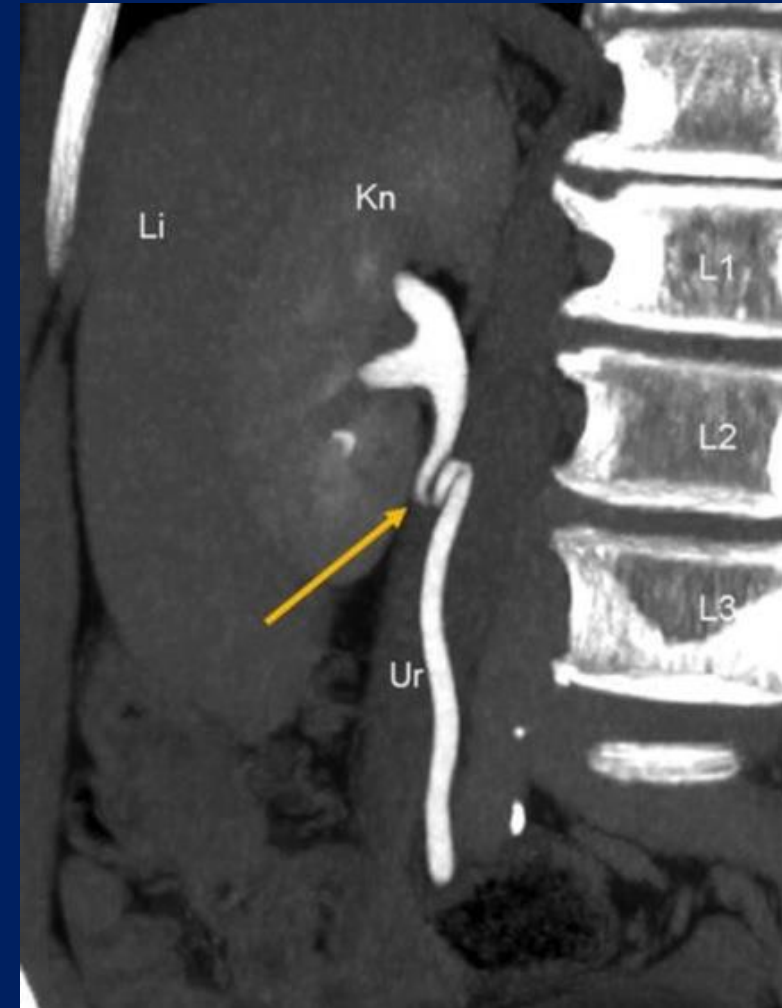8/12/2025

Dr Kishore S Dharan
Consultant Nephrologist
MOSC Medical College, Kolenchery

Question No: 1

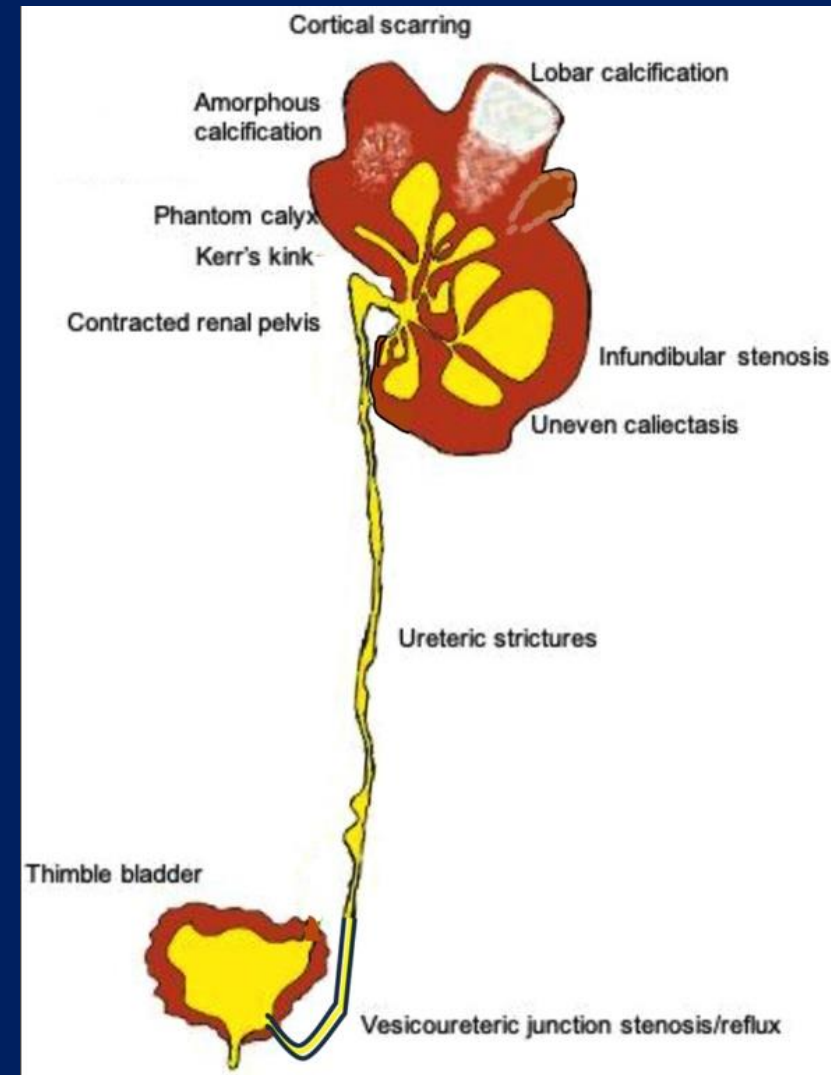
In the context of a CT Urogram, with which disease is the “Kerr Kink sign” typically associated with?

1. Reflux nephropathy
2. Papillary Necrosis
3. Renal tuberculosis
4. Schistosomiasis



Ans: C. RENALTUBERCULOSIS

- The **Kerr kink sign** is a specific radiologic finding in Genito urinary tuberculosis
- Characterized by a sharp bend or angulation at the ureteropelvic junction
- Caused by scarring and fibrosis from chronic inflammation, pulling on the kidney's pelvis and ureter



FIRST QUESTION WINNER

DrSunil kumar Behera
2nd year DM Nephrology
Resident
AIIMS Raipur.



Question No: 2

In which of the following situations treatment of **asymptomatic candiduria** is not indicated?

- A. 6 months post renal transplant
- B. Very low birth weight neonate
- C. Neutropenia
- D. Planned urologic surgery

ANS: A 6 months post renal transplant

- Elimination of predisposing factors, such as indwelling bladder catheters
- Treatment with antifungal agents is NOT recommended unless the patient belongs to a group at high risk for dissemination;
 - high-risk patients include neutropenic patients,
 - very low-birth-weight infants (<1500 g)
 - patients who will undergo urologic manipulation
- Patients undergoing urologic procedures should be treated with oral fluconazole, 400 mg (6 mg/kg) daily, OR AmB deoxycholate, 0.3–0.6 mg/kg daily, for several days before and after the procedure

SECOND QUESTION WINNER

Dr. Shubham

DM nephrology Senior
Resident 2nd year

Aiims Raipur



Thank You